



March 2009 (updated May 2015)

# ELDER CARE

## A Resource for Interprofessional Providers

### Macular Degeneration

Barry D. Weiss, MD, College of Medicine, University of Arizona

Age-related macular degeneration (AMD) is the most common cause of irreversible blindness among older adults in the United States. The prevalence of AMD increases with age and indeed, age is the strongest risk factor. AMD affects some 10% of individuals between 66-74 years of age, but the rate increases to 30% in those 75 and older. One of every 14 people over aged 75 has advanced AMD with significant visual impairment.

AMD is most common in whites, followed by Native Americans, Hispanics, Asians, and blacks. These racial differences may relate to the presence of genetic polymorphisms, which are thought to account for up to three-quarters of cases of AMD. Current or past smoking is also a strong risk factor for AMD, as are obesity, hypertension, high-fat diets, and low intake of antioxidants.

#### Clinical Presentation

AMD progresses through stages (Table 1). In its earliest stage, AMD is often asymptomatic. As the disease progresses and symptoms develop, AMD can seriously impair vision because the disease involves the macula – the central area of the retina responsible for highest-resolution color vision. Early symptoms include the need for more light when reading and a decrease in the intensity of colors (Table 2). As AMD progresses, loss of central visual acuity occurs and patients experience blurriness of printed words, difficulty recognizing faces, and in later stages, blind spots in the central visual field.

#### Examination

A review by the Cochrane Collaboration found no evidence that routine screening changes outcomes for patients with AMD, and therefore routine vision screening

of all older adults is not recommended. When older adults complain of visual symptoms, however, such as those in Table 2, AMD should be considered as a diagnostic possibility.

Physical exam findings in early AMD include the presence of drusen on funduscopic exam (Figure 1). Drusen are small yellow or off-white extracellular protein and lipid deposits that form either in the tissue layer underneath the retina or on the optic nerve head. The exact cause of drusen is unknown, but its presence on the macula of the retina strongly suggests AMD. Referral to an ophthalmologist should be made to confirm the diagnosis.

Another office based assessment that can be used to assess for AMD when older patients complain of visual symptoms is an Amsler grid (Figure 2). Patients view the grid through each eye separately and report if they see wavy distortions (metamorphopsia) or breaks in the grid pattern. Patients reporting such abnormalities should be referred to an ophthalmologist.

**Table 1. Stages of Age-Related Macular Degeneration**

Stage	Findings on Retinal Examination
Early	Small numbers of drusen
Intermediate	Numerous drusen, some large; geographic atrophy not involving the macula
Advanced non-neovascular	Drusen and geographic atrophy involving the macula
Advanced neovascular	Choroidal neovascularization that may result in hemorrhage or retinal detachment

#### TIPS ABOUT MACULAR DEGENERATION

- Recommend smoking cessation, maintaining a healthy weight, and consuming a healthy diet, all of which reduce the risk of AMD.
- When drusen are seen on ophthalmoscopic exam, suspect AMD and refer the patient to an ophthalmologist.
- Consider using an Amsler Grid for preliminary assessment of older patients with visual complaints.
- Individualize vitamin and mineral therapy for AMD (see text) to avoid adverse effects.

# ELDER CARE

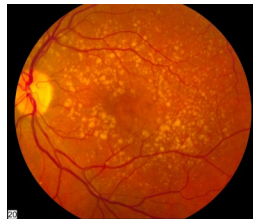Continued from front page

## Treatment

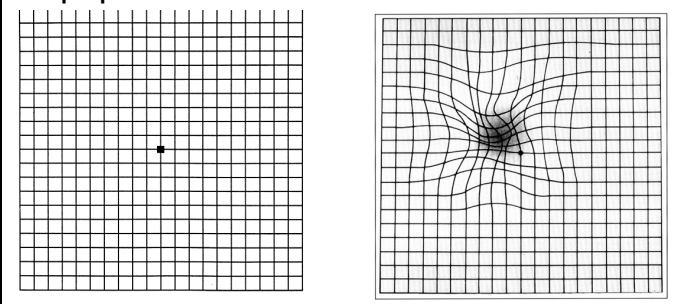
All stages of AMD are treated with lifestyle modification to lower the risk of progression to advanced neovascular AMD. Recommendations include smoking cessation, weight loss if overweight, control of hypertension, and increased dietary intake of antioxidants including beta-carotene, vitamins C and E and zinc. Large-scale AMD studies also suggest that supplemental vitamins and minerals (Table 3), in addition to dietary intake, can reduce the rate with which intermediate and advanced non-neovascular AMD progress to neovascular AMD. Use of these supplements should be individualized, however, because in other research, beta-carotene supplementation has been linked to lung cancer in smokers, and vitamin E has been linked to heart failure in people with diabetes or cardiac disease.

**Figure 1. Drusen**  
(German meaning “stony granule”)

Drusen can be seen on a routine ophthalmoscopic exam



**Figure 2. Amsler Grid.** Left shows grid as seen by an individual with normal vision. Right shows grid as seen by an individual with metamorphopsia of AMD.



### Image Credits:

National Eye Institute, National Institutes of Health

## References and Resources

- American Academy of Ophthalmology. Age-Related Macular Degeneration, Preferred Practice Pattern. San Francisco: American Academy of Ophthalmology, 2008. [http://one.gao.org/CE/PracticeGuidelines/PPP\\_Content.aspx?cid=f413917a-8623-4746-b441-f817265eafb4](http://one.gao.org/CE/PracticeGuidelines/PPP_Content.aspx?cid=f413917a-8623-4746-b441-f817265eafb4)
- Jager RD, Meiler WF, Miller JW. Age-related macular degeneration. *N Eng J Med.* 2008; 358:2606-14.
- Smeeth LL, Ilife S, Community screening for visual impairment in the elderly. *Cochrane Database of Systematic Reviews* 2006. <http://onlinelibrary.wiley.com/doi/10.1002/14651858.CD001054.pub2/full>
- Summary of study results from the Age-Related Eye Disease Study. <http://www.ncbi.nlm.nih.gov/pmc/articles/PMC1473209/>

**Neovascular AMD**, also called wet macular degeneration, usually develops from dry AMD and presents suddenly and with rapid vision loss. This disease is frequently treated with intravitreal injections of antiangiogenic agents, laser therapy, and/or a variety of experimental treatments and devices. More information about these treatments can be found in the references and resources listed below.

## Visual Aids

For patients with severe visual loss, several visual aids are available. These include video magnifiers, telescopes mounted on eyeglasses, and others. Another issue of Elder Care addresses these visual aids.

**Table 2. Symptoms of Age Related Macular Degeneration**

Early Symptoms	Late Symptoms
Need for brighter light	Difficulty recognizing faces
Decreased intensity of colors	Hazy overall vision
Metamorphopsia (wavy distortions)	Blurred or blind spot in central vision

**Table 3. Vitamin and Mineral Doses Used for Intermediate and Advanced AMD**

Vitamin C	500 mg/day
Vitamin E	400 IU/day
Beta-carotene	15 mg/day
Zinc oxide	80 mg/day
Cupric oxide	2 mg/day

## Interprofessional care improves the outcomes of older adults with complex health problems

Editors: Mindy Fain, MD; Jane Mohler, NP-c, MPH, PhD; and Barry D. Weiss, MD

Interprofessional Associate Editors: Tracy Carroll, PT, CHT, MPH; David Coon, PhD; Jeannie Lee, PharmD, BCPS;

Lisa O'Neill, MPH; Floribella Redondo; Laura Vitkus, BA

The University of Arizona, PO Box 245069, Tucson, AZ 85724-5069 | (520) 626-5800 | <http://aging.medicine.arizona.edu>

Supported by: Donald W. Reynolds Foundation, Arizona Geriatric Education Center and Arizona Center on Aging

This project was supported by the Health Resources and Services Administration (HRSA) of the U.S. Department of Health and Human Services (HHS) under grant number UB4HP19047, Arizona Geriatric Education Center. This information or content and conclusions are those of the author and should not be construed as the official position or policy of, nor should any endorsements be inferred by HRSA, HHS or the U.S. Government.