



July 2009 (updated May 2015)

# ELDER CARE

## A Resource for Interprofessional Providers

### **Pain When Reaching Overhead: Four Common Shoulder Problems in Older Adults**

Peter J. Millett, MD, MSc, Board Certified, American Board of Orthopedic Surgery, Steadman Hawkins Clinic  
Barry D. Weiss, MD, College of Medicine, University of Arizona

Shoulder problems occur frequently in older adults. Four syndromes are particularly frequent, and they all share the common symptom of pain when reaching overhead: (1) rotator cuff tendinitis or impingement syndrome, (2) rotator cuff tear, (3) osteoarthritis, and (4) frozen shoulder. In addition to pain, each can cause significant long-term disability.

Many providers find it difficult to distinguish these shoulder syndromes from one another. This issue of Elder Care will briefly review the four conditions and provide an algorithm that outlines a diagnostic approach for distinguishing them.

#### **Rotator Cuff Tendinitis or Impingement**

Patients with this condition often notice pain on reaching upward, such as when putting on a sweater or turning a steering wheel. May be painful to sleep on the affected side. Examination shows good active and passive range of motion, but active motion is painful when doing things like reaching overhead, clasping hands behind the neck, or scratching the lower back. Arm abduction will typically cause pain between 60-120° of the arc. Plain x-rays should be ordered and may show an offending bone spur, but MRI is the best test to visualize tendons of the rotator cuff. MRI should be obtained if surgical repair is being considered.

Conservative treatment consists of icing the shoulder for 15-20 minutes 2-3 times daily, non-steroidal anti-inflammatory drugs (NSAIDs), which should be used cautiously as they may cause renal impairment in older adults, plus physical therapy for range of motion and shoulder-strengthening exercises. Surgery may be needed for those who do not respond to these measures.

#### **Rotator Cuff Tear**

Patients with this condition present with pain over the lateral deltoid. They also have weakness and are typically unable to lift even a small (2 lb) weight overhead. The key physical findings are the “lag sign” or “drop arm” sign. The “lag” is the difference between passive range of motion, which is typically unrestricted, and active range of motion, which is limited. For the drop test, have the patient stand and passively move their arm away from the body (abduct) to 90 degrees. With the arm at shoulder level, the patient is asked to keep the arm in that position as the examiner lets go. If the arm sinks (the drop-arm sign), a cuff tear is likely. With larger tears, plain x-rays will show upward displacement of the humeral head, but MRI is the most accurate imaging modality and will not only demonstrate the size of the tear but also the degree of muscle atrophy and fatty infiltration, all of which affect the prognosis for successful repair.

Acute rotator cuff tears should be repaired surgically within 6 weeks of injury. For chronic tears, surgery may still be beneficial but a non-operative approach may also be considered first using ice, NSAIDs, and physical therapy with gentle range-of-motion exercises. Steroid injections may also be helpful. A Cochrane Review of corticosteroid injections for shoulder pain found a mild, short-term (4-week) benefit with respect to pain, however no meaningful long-term benefit compared with other therapies.

#### **Osteoarthritis**

Osteoarthritis of the shoulder often presents with posterior shoulder pain that can extend to the muscles of the upper

#### **TIPS FOR EVALUATING AND TREATING SHOULDER PROBLEMS IN OLDER ADULTS**

- If pain occurs during abduction at 60-120° of arc, a rotator cuff problem - either tendinitis/impingement or a tear – is the likely diagnoses.
- Passively abduct the patient’s arm to 90° and ask the patient to hold the arm in that position when you let go. If the arm sinks (positive drop-arm sign) or there is weakness, a rotator cuff tear is the likely diagnosis.
- Obtain MRI to confirm rotator cuff tear. Acute complete tears should be repaired within 6 weeks of injury.
- If crepitus or grinding occurs when moving the arm against resistance, osteoarthritis is the likely diagnosis.
- If both active and passive movement is restricted, frozen shoulder or osteoarthritis are the likely diagnoses. X-ray can then help distinguish between these two diagnoses.

# ELDER CARE

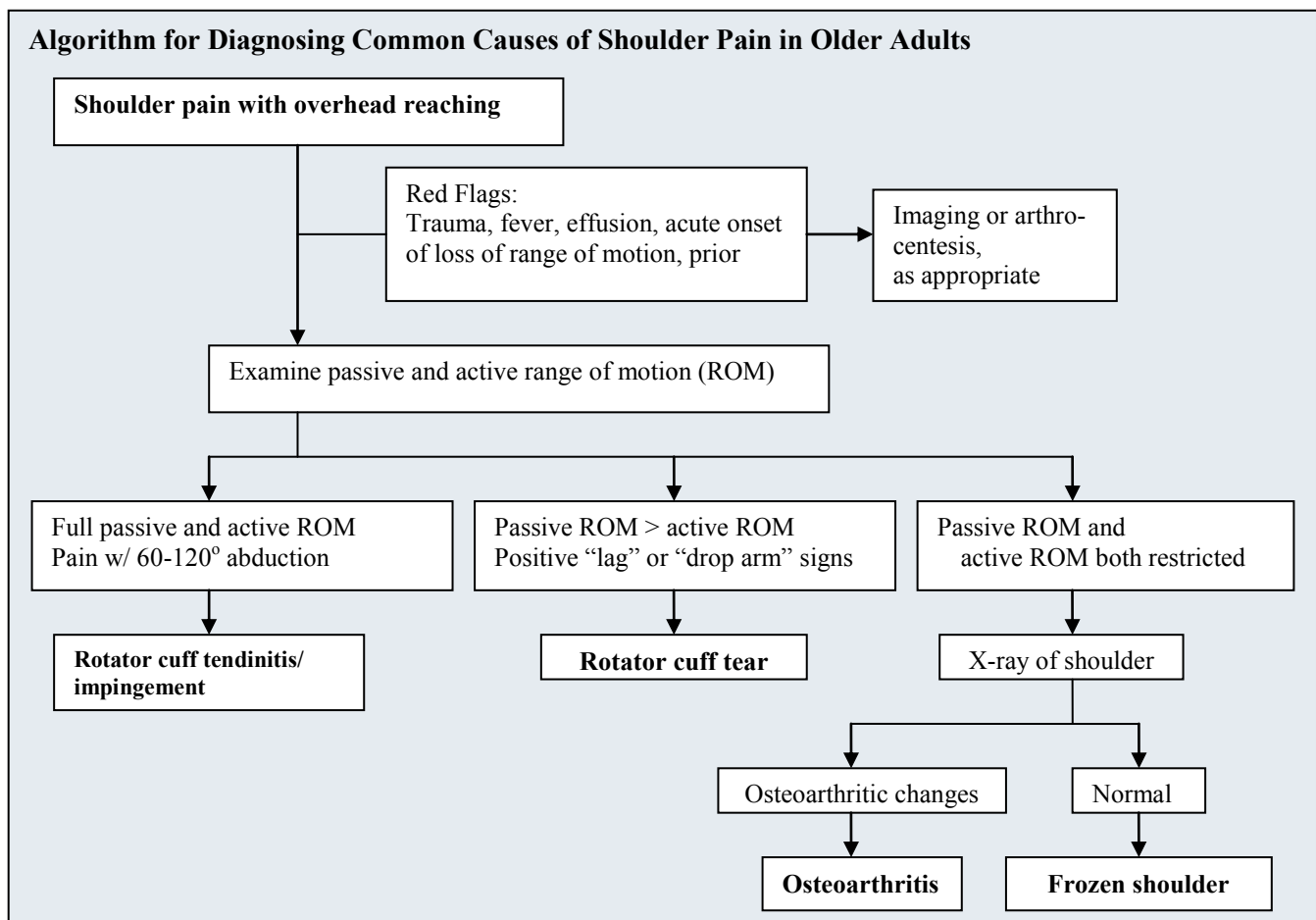
Continued from front page

arm. Patients may feel pain and crepitation or grinding when lifting objects. Examination shows loss of both active and passive motion, sometimes with audible or palpable crepitus during movement against resistance. Strength is usually preserved, though limited by pain. Plain x-rays show osteoarthritic changes of joint-space narrowing, sclerosis, and bone spurs. Treatment includes ice, NSAIDs, acetaminophen, and steroid injections into the shoulder joint. The latter provides only temporary relief, but relief following the injection helps confirm the diagnosis. Arthroscopic debridement and total shoulder arthroplasty are effective treatments for cases refractory to non-operative therapy.

## Frozen Shoulder

Patients with frozen shoulder have stiffness and difficulty

with all motion. Both active and passive motion are severely limited, distinguishing frozen shoulder from the other conditions discussed thus far. Patients often cannot put on a coat or scratch their back and are unable to touch their scapula from above or below. Plain x-rays should be obtained but are typically normal and show a preserved joint space. With NSAIDs and physical therapy for range of motion and strengthening exercises, most patients will improve, though recovery can take 6-18 months. Intra-articular steroid injections can be helpful in the early stages to decrease the inflammation that is seen in the capsule. For refractory cases, it may be necessary to perform arthroscopic capsular release or joint manipulation under anesthesia to break up adhesions.



## References and Resources

Buchbinder R, Green S, Youd JM. Corticosteroid injections for shoulder pain (Cochrane Review). In: The Cochrane Library, Issue 2, 2004. Chichester, UK: John Wiley & Sons.

Gomoll AH, Katz JN, Warner JJ, Millett PJ. Rotator cuff disorders: recognition and management among patients with shoulder pain. *Arthritis Rheum.* 2004;50:3751-61.

Matsen FA. Rotator cuff failure. *N Eng J Med.* 2008; 358: 2138-47.

## Interprofessional care improves the outcomes of older adults with complex health problems

Editors: Mindy Fain, MD; Jane Mohler, NP-c, MPH, PhD; and Barry D. Weiss, MD

Interprofessional Associate Editors: Tracy Carroll, PT, CHT, MPH; David Coon, PhD; Jeannie Lee, PharmD, BCPS;

Lisa O'Neill, MPH; Floribella Redondo; Laura Vitkus, BA

The University of Arizona, PO Box 245069, Tucson, AZ 85724-5069 | (520) 626-5800 | <http://aging.medicine.arizona.edu>

Supported by: Donald W. Reynolds Foundation, Arizona Geriatric Education Center and Arizona Center on Aging

This project was supported by the Health Resources and Services Administration (HRSA) of the U.S. Department of Health and Human Services (HHS) under grant number UB4HP19047, Arizona Geriatric Education Center. This information or content and conclusions are those of the author and should not be construed as the official position or policy of, nor should any endorsements be inferred by HRSA, HHS or the U.S. Government.